

PennHIP Report

Referring Veterinarian: Dr Kipp Magnussen

Clinic Name: Standiford Veterinary Hospital
and Emergency Clinic

Email: klmagnussen@sylvanvet.com

Clinic Address: 1520 Standiford Ave.
Modesto, CA 95350

Phone:

Fax:

Patient Information

Client: Borbon, Megan

Tattoo Num:

Patient Name: Naranjo Hills Giorgino

Patient ID: 22303 E

Reg. Name:

Registration Num:

PennHIP Num: 190322

Microchip Num:

Species: Canine

Breed: MAREMMA SHEEPDOG

Date of Birth: 18 Feb 2023

Age: 16 weeks

Sex: Male

Weight: 41.2 lbs/18.7 kgs

Date of Study: 14 Jun 2023

Date Submitted: 15 Jun 2023

Date of Report: 19 Jun 2023

Findings

Distraction Index (DI): Right DI = 0.38, Left DI = 0.39.

Osteoarthritis (OA): **No radiographic evidence of OA for either hip.**

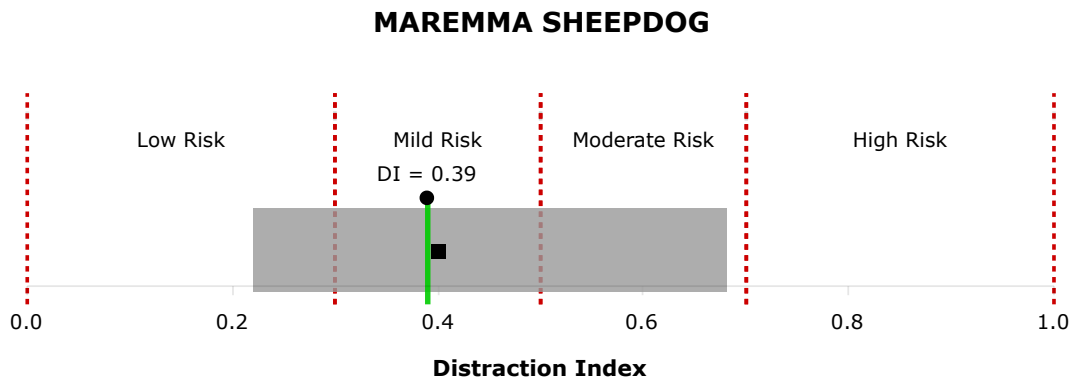
Cavitation/Other Findings: No cavitation present.

Interpretation

Distraction Index (DI): The laxity ranking is based on the hip with the greater laxity (larger DI). In this case the DI used is 0.39.

OA Risk Category: The DI is between 0.31 and 0.49. This patient is at mild risk for hip OA.

Distraction Index Chart:



BREED STATISTICS: This interpretation is based on a cross-section of 243 canine patients of the MAREMMA SHEEPDOG breed in the AIS PennHIP database. The gray strip represents the central 90% range of DIs (0.22 - 0.68) for the breed. The breed average DI is 0.40 (solid square). The patient DI is the solid circle (0.39).

SUMMARY: The degree of laxity (DI = 0.39) falls within the central 90% range of DIs for the breed. This amount of hip laxity places the hip at a mild risk to develop hip OA. **No radiographic evidence of OA for either hip.**

