

PennHIP Report

Referring Veterinarian: Dr Jeaneen Metzler Email: orangevalevet@yahoo.com	Clinic Name: Orangevale Veterinary Hospital Clinic Address: 6248 Main Ave #D Orangevale, CA 95662 Phone: (916) 987-2055 Fax: (916) 987-2052
--	---

Patient Information

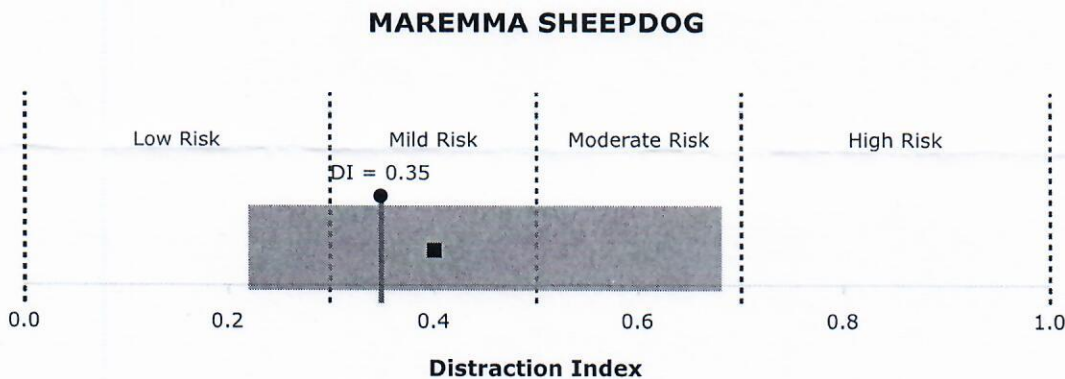
Client: Spencer, Becky Patient Name: Bolo Reg. Name: Unfinished Acres Bolo PennHIP Num: 158807 Species: Canine Date of Birth: 06 Oct 2020 Sex: Female Date of Study: 22 Jun 2021 Date of Report: 24 Jun 2021	Tattoo Num: Patient ID: 956000005160645 Registration Num: Microchip Num: Breed: MAREMMA SHEEPDOG Age: 8 months Weight: 65 lbs/29.5 kgs Date Submitted: 22 Jun 2021
--	---

Findings

Distraction Index (DI): Right DI = 0.29, Left DI = 0.35. Osteoarthritis (OA): No radiographic evidence of OA for either hip. Cavitation/Other Findings: No cavitation present.

Interpretation

Distraction Index (DI): The laxity ranking is based on the hip with the greater laxity (larger DI). In this case the DI used is 0.35.
 OA Risk Category: The DI is between 0.31 and 0.49. This patient is at mild risk for hip OA.
 Distraction Index Chart:



BREED STATISTICS: This interpretation is based on a cross-section of 213 canine patients of the MAREMMA SHEEPDOG breed in the AIS PennHIP database. The gray strip represents the central 90% range of DIs (0.22 - 0.68) for the breed. The breed average DI is 0.40 (solid square). The patient DI is the solid circle (0.35).

SUMMARY: The degree of laxity (DI = 0.35) falls within the central 90% range of DIs for the breed. This amount of hip laxity places the hip at a mild risk to develop hip OA. **No radiographic evidence of OA for either hip.**