

PennHIP Report

Referring Veterinarian: Dr Kipp Magnussen	Clinic Name: Standiford Veterinary Hospital and Emergency Clinic
Email: klmagnussen@sylvanvet.com	Clinic Address: 1520 Standiford Ave. Modesto, CA 95350
	Phone:
	Fax:

Patient Information

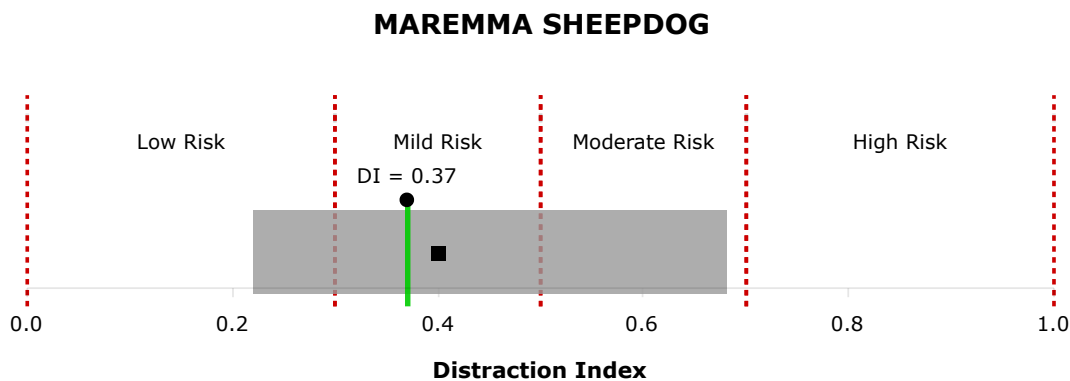
Client: Borbon, Megan	Tattoo Num:
Patient Name: Naranjo Hills Louie	Patient ID: 22303 G
Reg. Name:	Registration Num:
PennHIP Num: 190315	Microchip Num:
Species: Canine	Breed: MAREMMA SHEEPDOG
Date of Birth: 18 Feb 2023	Age: 16 weeks
Sex: Male	Weight: 41 lbs/18.6 kgs
Date of Study: 14 Jun 2023	Date Submitted: 15 Jun 2023
Date of Report: 20 Jun 2023	

Findings

Distraction Index (DI): Right DI = 0.36, Left DI = 0.37.
Osteoarthritis (OA): No radiographic evidence of OA for either hip.
Cavitation/Other Findings: No cavitation present.

Interpretation

Distraction Index (DI): The laxity ranking is based on the hip with the greater laxity (larger DI). In this case the DI used is 0.37.
 OA Risk Category: The DI is between 0.31 and 0.49. This patient is at mild risk for hip OA.
 Distraction Index Chart:



BREED STATISTICS: This interpretation is based on a cross-section of 243 canine patients of the MAREMMA SHEEPDOG breed in the AIS PennHIP database. The gray strip represents the central 90% range of DIs (0.22 - 0.68) for the breed. The breed average DI is 0.40 (solid square). The patient DI is the solid circle (0.37).

SUMMARY: The degree of laxity (DI = 0.37) falls within the central 90% range of DIs for the breed. This amount of hip laxity places the hip at a mild risk to develop hip OA. **No radiographic evidence of OA for either hip.**